

REVIEW ARTICLE

Lindsey R. Baden, M.D., *editor*

Zika Virus

Lyle R. Petersen, M.D., M.P.H., Denise J. Jamieson, M.D., M.P.H.,
Ann M. Powers, Ph.D., and Margaret A. Honein, Ph.D., M.P.H.

From the Division of Vector-Borne Diseases, National Center for Emerging and Zoonotic Infectious Diseases, Centers for Disease Control and Prevention, Fort Collins, CO (L.R.P., A.M.P.); and the Division of Reproductive Health, National Center for Chronic Disease Prevention and Health Promotion (D.J.J.), and the Division of Congenital and Developmental Disorders, National Center on Birth Defects and Developmental Disabilities (M.A.H.), Centers for Disease Control and Prevention, Atlanta. Address reprint requests to Dr. Petersen at the Division of Vector-Borne Diseases, Centers for Disease Control and Prevention, 3156 Rampart Rd., Fort Collins, CO 80521, or at lrp2@cdc.gov.

This article was published on March 30, 2016, at NEJM.org.

N Engl J Med 2016;374:1552-63.

DOI: 10.1056/NEJMr1602113

Copyright © 2016 Massachusetts Medical Society.

IN 1947, A STUDY OF YELLOW FEVER YIELDED THE FIRST ISOLATION OF A NEW virus, from the blood of a sentinel rhesus macaque that had been placed in the Zika Forest of Uganda.¹ Zika virus remained in relative obscurity for nearly 70 years; then, within the span of just 1 year, Zika virus was introduced into Brazil from the Pacific Islands and spread rapidly throughout the Americas.² It became the first major infectious disease linked to human birth defects to be discovered in more than half a century and created such global alarm that the World Health Organization (WHO) would declare a Public Health Emergency of International Concern.³ This review describes the current understanding of the epidemiology, transmission, clinical characteristics, and diagnosis of Zika virus infection, as well as the future outlook with regard to this disease.

EPIDEMIOLOGY

Zika virus is a flavivirus, in the family Flaviviridae. Although Zika virus was isolated on several occasions from *Aedes africanus* mosquitoes after its discovery in 1947,⁴ there initially was no indication that the virus caused human disease. Nevertheless, a serosurvey involving residents of multiple areas of Uganda revealed a 6.1% seroprevalence of antibodies against Zika virus, which suggested that human infection was frequent.⁵ Additional serosurveys indicated a much broader geographic distribution of human infection, including Egypt,⁶ East Africa,⁷ Nigeria,⁸ India,⁹ Thailand,¹⁰ Vietnam,¹⁰ the Philippines,¹¹ and Malaysia (near Kuala Lumpur and in East Malaysia [Sabah and Federal Territory of Labuan]).¹²

Human illness caused by Zika virus was first recognized in Nigeria in 1953, when viral infection was confirmed in three ill persons.⁸ Despite recognition that Zika virus infection could produce a mild, febrile illness, only 13 naturally acquired cases were reported during the next 57 years.¹³⁻¹⁶ Thus, it came as a great surprise when a 2007 outbreak on several islands in the State of Yap, Federated States of Micronesia, resulted in an estimated 5000 infections among the total population of 6700.¹⁷

Subsequently, an outbreak in French Polynesia in 2013 and 2014 is estimated to have involved 32,000 persons who underwent evaluation for suspected Zika virus infection.¹⁸⁻²⁰ Although most of the illnesses appeared similar to those seen in Yap, cases of Guillain-Barré syndrome were also noted.^{19,21} Subsequent outbreaks occurred on other Pacific islands, including New Caledonia (in 2014),²² Easter Island (2014),²³ Cook Islands (2014),²⁴ Samoa (2015), and American Samoa (2016) (Fig. 1). In stark contrast to these outbreaks, in the past 6 years, only sporadic cases of Zika virus infection have been reported in Thailand,^{25,26} East Malaysia (Sabah),²⁷ Cambodia,²⁸ the Philippines,²⁹ and Indonesia.^{30,31}

Zika virus was first identified in the Americas in March 2015, when an outbreak

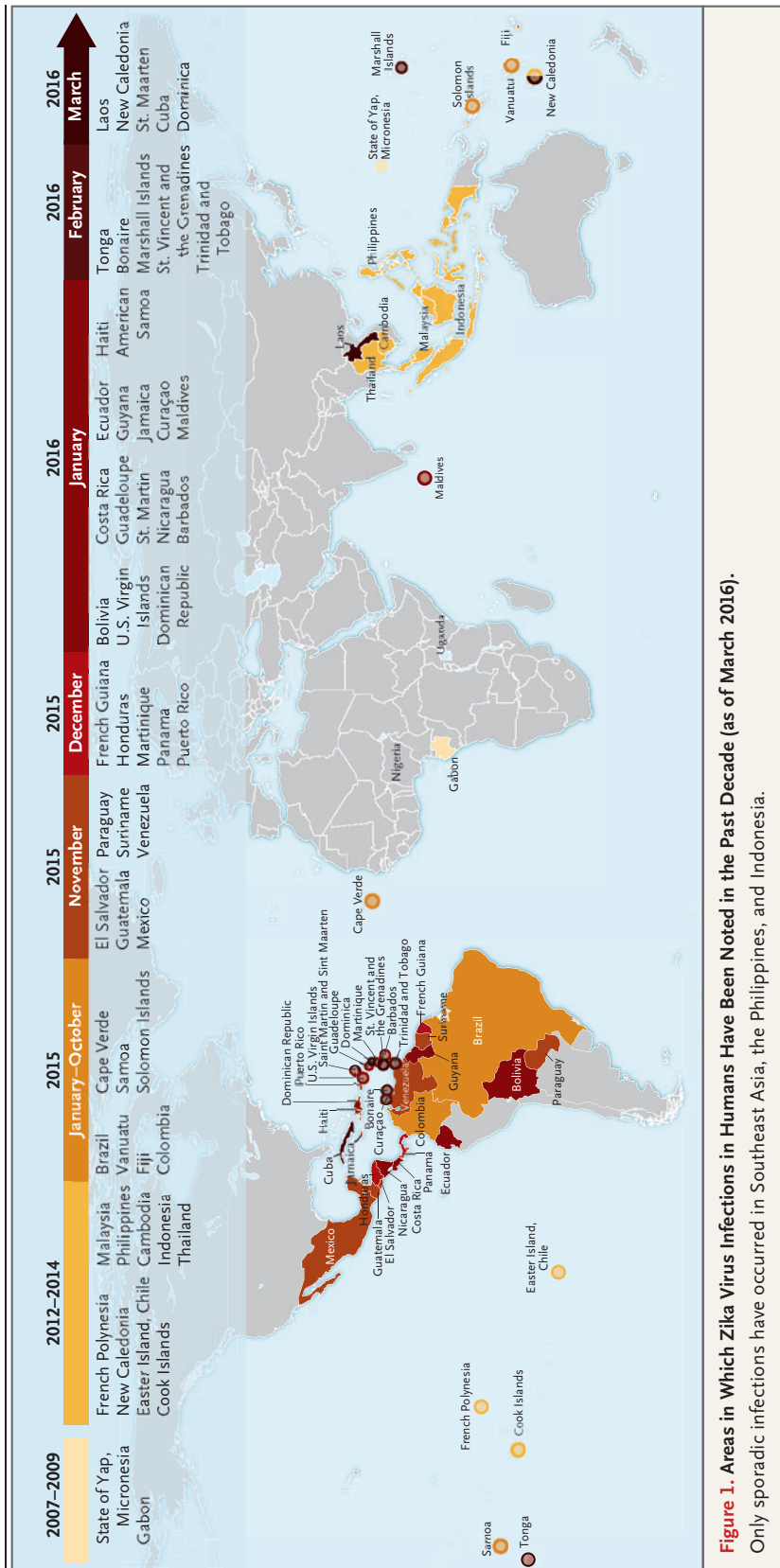


Figure 1. Areas in Which Zika Virus Infections in Humans Have Been Noted in the Past Decade (as of March 2016).
 Only sporadic infections have occurred in Southeast Asia, the Philippines, and Indonesia.

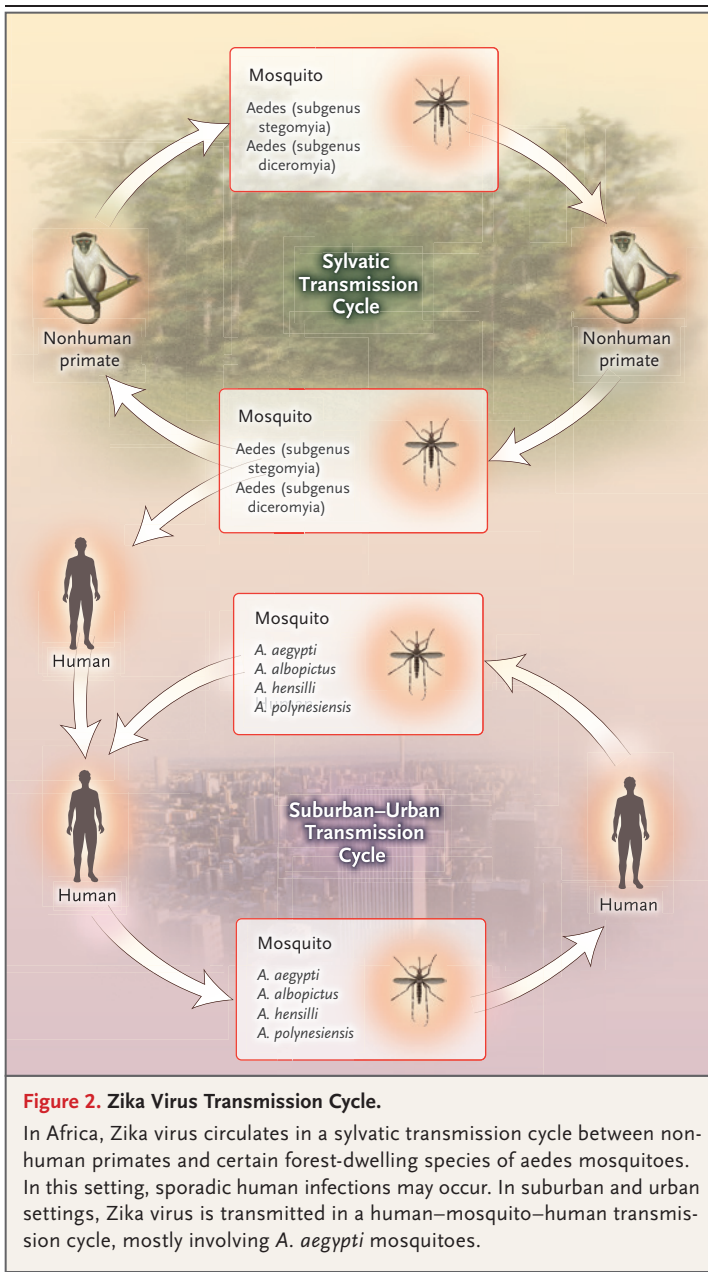


Figure 2. Zika Virus Transmission Cycle.

In Africa, Zika virus circulates in a sylvatic transmission cycle between nonhuman primates and certain forest-dwelling species of *Aedes* mosquitoes. In this setting, sporadic human infections may occur. In suburban and urban settings, Zika virus is transmitted in a human–mosquito–human transmission cycle, mostly involving *A. aegypti* mosquitoes.

of an exanthematous illness occurred in Bahia, Brazil.^{32,33} Epidemiologic data indicate that in Salvador, the capital of Bahia, the outbreak had begun in February and extended to June 2015.³⁴ By October, the virus had spread to at least 14 Brazilian states,³⁵ and in December 2015, the Brazil Ministry of Health estimated that up to 1.3 million suspected cases had occurred.³⁶ In October 2015, Colombia reported the first autochthonous transmission of Zika virus outside Brazil,³⁵ and by March 3, 2016, a total of 51,473

suspected cases of Zika virus had been reported in that country.³⁷ By March 2016, the virus had spread to at least 33 countries and territories in the Americas (Fig. 1).^{36,37}

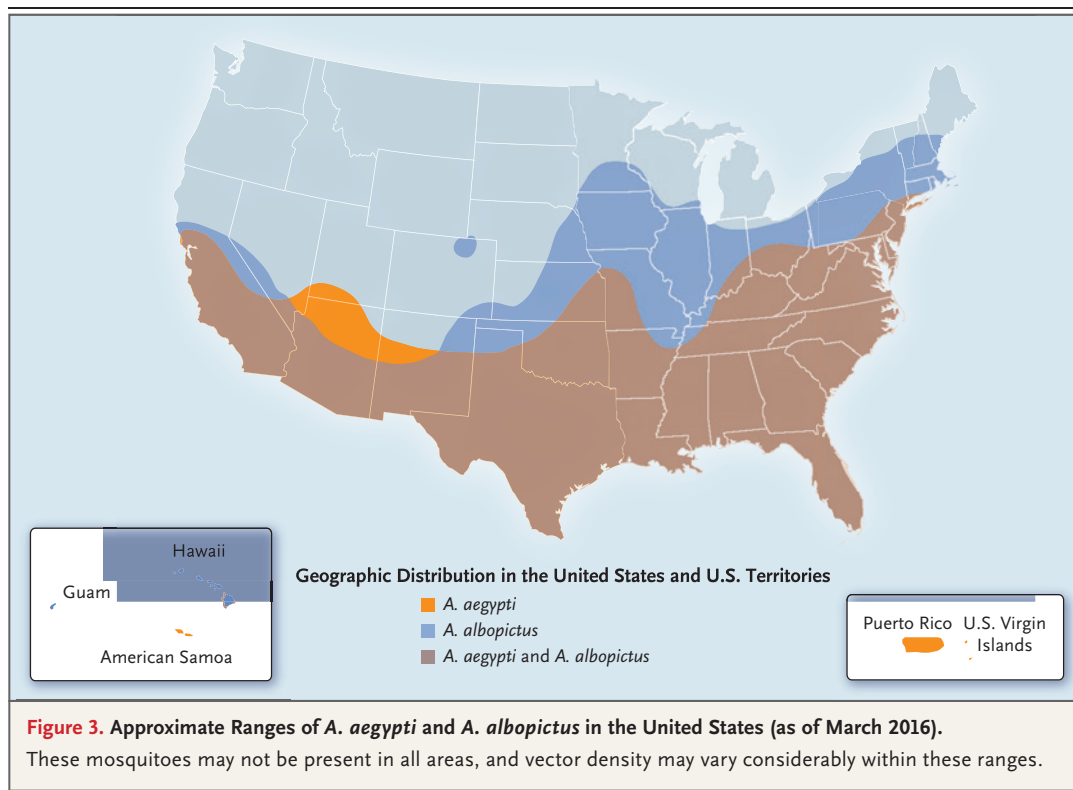
By September 2015, investigators in Brazil noted an increase in the number of infants born with microcephaly in the same areas in which Zika virus was first reported,³⁸ and by mid-February 2016, more than 4300 cases of microcephaly had been recorded, although overreporting and misdiagnosis probably inflated this number.³⁹ Subsequently, French Polynesian investigators retrospectively identified an increased number of fetal abnormalities, including microcephaly, after the Zika virus outbreak in that country.^{40,41}

ZIKA VIRUS TRANSMISSION

MOSQUITO-BORNE TRANSMISSION

In Africa, Zika virus exists in a sylvatic transmission cycle involving nonhuman primates and forest-dwelling species of *Aedes* mosquitoes (Fig. 2). In Asia, a sylvatic transmission cycle has not yet been identified. Several mosquito species, primarily belonging to the *stegomyia* and *diceromyia* subgenera of *Aedes*, including *A. africanus*, *A. luteocephalus*, *A. furcifer*, and *A. taylori*, are likely enzootic vectors in Africa and Asia.^{42,43}

In urban and suburban environments, Zika virus is transmitted in a human–mosquito–human transmission cycle (Fig. 2). Two species in the *stegomyia* subgenus of *Aedes* — *A. aegypti* and, to a lesser extent, *A. albopictus*⁴⁴ — have been linked with nearly all known Zika virus outbreaks, although two other species, *A. hensilli* and *A. polynesiensis*, were thought to be vectors in the Yap⁴⁵ and French Polynesia⁴⁶ outbreaks, respectively. *A. aegypti* and *A. albopictus* are the only known *Aedes* (*stegomyia*) species in the Americas. Despite the association of *A. aegypti* and *A. albopictus* with outbreaks, both were found to have unexpectedly low but similar vector competence (i.e., the intrinsic ability of a vector to biologically transmit a disease agent) for the Asian genotype Zika virus strain, as determined by a low proportion of infected mosquitoes with infectious saliva after ingestion of an infected blood meal.⁴⁷ However, *A. aegypti* is thought to have high vectorial capacity (i.e., the overall ability of a vector species to transmit a pathogen in a given location and at a specific time) because it feeds primarily on humans, often bites multi-



ple humans in a single blood meal, has an almost imperceptible bite, and lives in close association with human habitation.⁴⁸

Both *A. aegypti* and *A. albopictus* bite primarily during the daytime and are widely distributed throughout the tropical and subtropical world. *A. albopictus* can exist in more temperate areas than *A. aegypti*, thus extending the potential range where outbreaks may occur. In the United States, *A. aegypti* is endemic throughout Puerto Rico and the U.S. Virgin Islands and in parts of the contiguous United States and Hawaii (Fig. 3).⁴⁹ *A. albopictus* is widely distributed in the eastern United States and Hawaii. Nevertheless, in the contiguous United States, contemporary outbreaks of dengue, which has a transmission cycle similar to that of Zika virus, have occurred only in areas in which *A. aegypti* is endemic, which suggests that the potential for the transmission of Zika virus elsewhere is limited. In contrast, Hawaii has experienced contemporary dengue outbreaks in which *A. albopictus* was the vector.^{50,51}

Zika virus has infrequently been identified in other mosquito species, such as *A. unilineatus*, *Anopheles coustani*, and *Mansonia uniformis*; how-

ever, vector-competence studies have indicated that these species have a low potential for transmission of the virus. It is notable that Zika virus has been reported only once in any culex species, which suggests that mosquitoes in this genus have a low vectorial capacity.⁴²

NONMOSQUITO TRANSMISSION

Substantial evidence now indicates that Zika virus can be transmitted from the mother to the fetus during pregnancy. Zika virus RNA has been identified in the amniotic fluid of mothers whose fetuses had cerebral abnormalities detected by ultrasonography,^{40,52-54} and viral antigen and RNA have been identified in the brain tissue and placentas of children who were born with microcephaly and died soon after birth,⁵⁵ as well as in tissues from miscarriages.^{54,55} The frequency of and risk factors for transmission are unknown.

Two cases of peripartum transmission of Zika virus have been reported among mother–infant pairs.⁵⁶ Zika virus RNA was detected in both infants; one infant had a mild rash illness and thrombocytopenia, whereas the other was asymptomatic.

Sexual transmission to partners of returning male travelers who acquired Zika virus infection abroad has been reported.⁵⁷⁻⁵⁹ In one instance, sexual intercourse occurred only before the onset of symptoms, whereas in other cases sexual intercourse occurred during the development of symptoms and shortly thereafter. The risk factors for and the duration of the risk of sexual transmission have not been determined. Replicative viral particles, as well as viral RNA — often in high copy numbers — have been identified in sperm, and viral RNA has been detected up to 62 days after the onset of symptoms.⁶⁰⁻⁶²

Although the transmission of Zika virus through a blood transfusion has yet to be reported, it is likely to occur, given the transmission of other, related flaviviruses through this route.⁶³ During the Zika virus outbreak in French Polynesia, 3% of donated blood samples tested positive for Zika virus by reverse-transcriptase polymerase chain reaction (RT-PCR).⁶⁴

One case of Zika virus transmission occurred after a monkey bite in Indonesia, although mosquito-borne transmission could not be ruled out.⁶⁵ Two infections in laboratories have been reported.^{16,66} A volunteer became infected after subcutaneous injection of infected mouse brain suspension.⁶⁷ Transmission through breast milk has not been documented, although the breast milk of a woman who became symptomatic with Zika virus infection on the day of delivery contained infective Zika viral particles in high titer.⁶⁸

CLINICAL ASPECTS

ACUTE FEBRILE ILLNESS

The incubation period for Zika virus is unknown, but if it is similar to that of other mosquito-borne flaviviruses, it is expected to be generally less than 1 week. In one volunteer, a febrile illness of 4 days' duration developed 82 hours after subcutaneous inoculation of Zika virus.⁶⁷ Viremia was detected when symptoms were present, but not afterward. Among French Polynesian blood donors who tested positive for Zika virus by RT-PCR, 11 (26%) reported conjunctivitis, rash, arthralgia, or a combination of these symptoms 3 to 10 days after donation.⁶⁴ Serosurvey results from Yap indicated that only 19% of persons who were infected had symptoms that were attributable to Zika virus.¹⁷ Common symptoms were macular or papular rash (90% of patients),

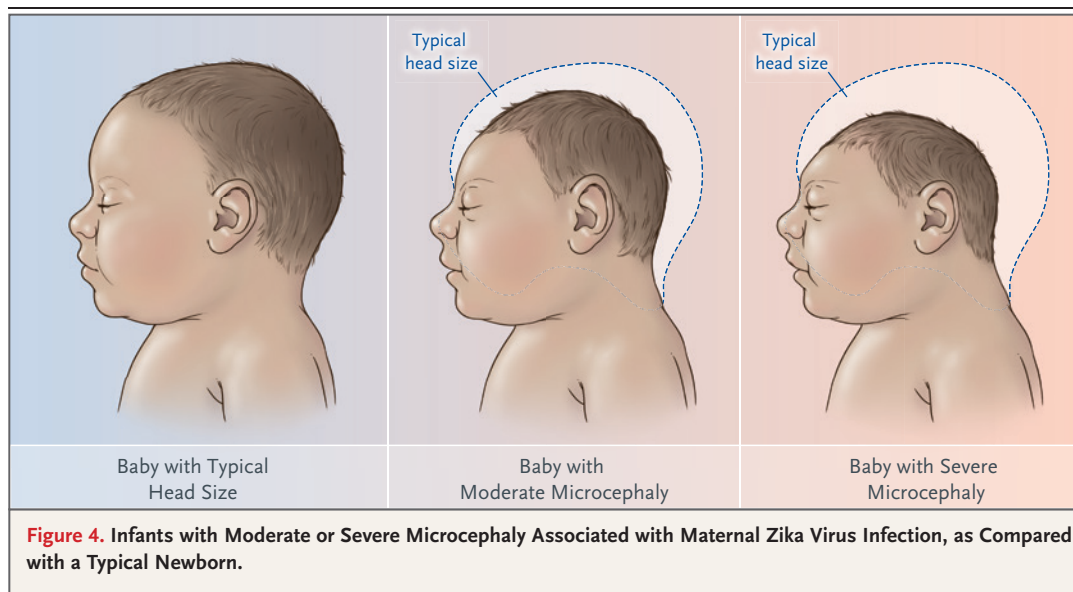
fever (65%), arthritis or arthralgia (65%), non-purulent conjunctivitis (55%), myalgia (48%), headache (45%), retro-orbital pain (39%), edema (19%), and vomiting (10%). No patient was hospitalized during the outbreak in Yap. These common symptoms occurred at frequencies similar to those in the Yap outbreak in a cohort of pregnant women with Zika virus infection in Brazil.⁶⁹ The rash is generally maculopapular and pruritic,⁶⁹ and fever, when present, is generally short-term and low-grade.⁶⁹ Other symptoms that have been noted in association with acute infection include hematospermia,^{57,60} transient dull and metallic hearing,²⁷ swelling of the hands and ankles,^{27,70} and subcutaneous bleeding.⁷¹

NEUROLOGIC COMPLICATIONS

A temporal and geographic relationship has been observed between Guillain-Barré syndrome and Zika virus outbreaks in the Pacific and the Americas.^{19,21,72-74} In the outbreak in French Polynesia, 38 cases of Guillain-Barré syndrome occurred among an estimated 28,000 persons who sought medical care.¹⁹ A case-control study in French Polynesia revealed a strong association (odds ratio, >34) between Guillain-Barré syndrome and previous Zika virus infection; the findings from electrophysiological studies were compatible with the acute motor axonal neuropathy subtype of Guillain-Barré syndrome.⁷⁵ Meningoencephalitis⁷⁶ and acute myelitis⁷⁷ complicating Zika virus infection also have been reported.

ADVERSE FETAL OUTCOMES

The full spectrum of fetal outcomes resulting from fetal Zika virus infection in humans is yet to be determined; however, the well-characterized effects of maternal infection with rubella virus and cytomegalovirus (CMV) may be instructive.^{78,79} Maternal rubella infections in the first 10 weeks of pregnancy can result in adverse fetal effects in up to 90% of infants and decrease thereafter, with a much lower risk after gestational week 18.^{80,81} The congenital anomalies associated with maternal rubella infection during pregnancy include sensorineural hearing loss, cataracts and other eye anomalies, cardiac anomalies, and neurologic effects, including intellectual disability, ischemic brain damage, and microcephaly.^{80,82} Similarly, maternal CMV infection can produce profound effects on the fetus,



including sensorineural hearing loss, chorio-retinitis, and neurologic effects, such as microcephaly, intellectual disability, and cerebral palsy.⁸³ For primary infections with CMV, the risk of adverse fetal effects is highest during the first trimester, but the risk persists in the second and third trimester, with some adverse fetal outcomes noted in mothers who had seroconversion after gestational week 27.⁸⁴ It is of particular concern that some infants without obvious adverse effects of congenital CMV infection at birth can have late-onset or progressive hearing loss that cannot be identified through screening of newborns.⁸⁵ Other causes of microcephaly include some genetic syndromes, vascular disruption during brain development, nutritional deficiencies, and exposure to certain toxins, such as mercury.⁸⁶

Microcephaly is a clinical finding of a small head size for gestational age and sex and is indicative of an underlying problem with the growth of the brain.⁸⁷ The lack of consistent and standardized case definitions has challenged the accurate monitoring of microcephaly during the current Zika virus outbreak.³⁹ Centers for Disease Control and Prevention (CDC) guidance has recommended that microcephaly be defined as an occipitofrontal circumference below the third percentile for gestational age and sex.⁸⁸ The prevalence of microcephaly in the United States averages approximately 6 cases per 10,000 live births, with a range of about 2 to 12 cases per

10,000 live births.⁸⁹ Because similar prevalences are expected in other countries, these figures may be suitable benchmarks for regions lacking accurate historical data.

Microcephaly can occur as a result of fetal brain disruption sequence, a process in which, after relatively normal brain development in early pregnancy, collapse of the fetal skull follows the destruction of fetal brain tissue.⁹⁰⁻⁹² Although previous case reports of maternal infection leading to fetal brain disruption sequence do not include information on the timing of maternal infection, some evidence indicates that this damage can occur late during the second trimester or even early in the third trimester.⁹³ Initial case reports from Brazil have suggested that some of the infants with microcephaly related to Zika virus infection have a phenotype consistent with fetal brain disruption (Fig. 4).^{38,94,95}

The findings of Zika virus RNA in the amniotic fluid of fetuses with microcephaly^{40,52,54} and in the brain tissue of fetuses and infants with microcephaly,^{55,94,95} as well as the high rates of microcephaly among infants born to mothers with proven antecedent acute Zika virus infection,⁶⁹ provide strong evidence linking microcephaly to maternal Zika virus infection. The timing of the Zika virus and microcephaly epidemics in Brazil^{96,97} and French Polynesia⁴¹ indicate that the greatest risk of microcephaly is in the first trimester. In case reports of microcephaly, documented maternal Zika virus infec-

tion most often occurred between 7 and 13 weeks of gestation, but in some cases it occurred as late as at 18 weeks of gestation.^{40,52,54,69,94}

A preliminary report from Brazil indicated that fetal abnormalities detected by ultrasonography were present in 29% of women with Zika virus infection during pregnancy.⁶⁹ Early fetal loss and fetal death have been noted in association with maternal infection that occurred between 6 and 32 weeks of gestation.^{54,69} Ocular anomalies have been reported among infants with microcephaly in Brazil.^{69,98-100} In the largest study with comprehensive ophthalmologic examinations of infants with microcephaly, ocular abnormalities were found in 10 of 29 patients (35%).¹⁰⁰ The most common ocular abnormalities were focal pigment mottling, chorioretinal atrophy, and optic-nerve abnormalities (hypoplasia and severe cupping of the optic disk). Other ocular manifestations in this and other case studies have included foveal reflex loss, macular neuroretinal atrophy, lens subluxation, and iris coloboma. Whether ocular manifestations occur after congenital Zika virus infection in infants without microcephaly remains unknown.

DIAGNOSIS

The mainstays of the routine diagnosis of Zika virus infection are the detection of viral nucleic acid by RT-PCR and the detection of IgM antibodies by IgM-capture enzyme-linked immunosorbent assay (MAC-ELISA). The detection of viral nucleic acid in serum provides a definitive diagnosis; however, in most instances viremia is transient, and diagnosis by RT-PCR has been most successful within 1 week after the onset of clinical illness.^{67,101} In contrast, viral RNA was detected in serum approximately 10 weeks after infection in a pregnant woman whose fetus had evidence of congenital infection.⁹⁵ In addition, viremia is generally low level, which makes viral isolation from clinical samples difficult.¹⁰¹ Although the precise timing of the onset and the duration of the IgM antibody response to Zika virus that is detectable by MAC-ELISA have not yet been defined, extensive experience with other, related flaviviruses suggests that IgM will appear as viremia wanes within the first week after symptom onset and will persist for several months.¹⁰² Thus, RT-PCR testing of serum samples obtained within the first week of clinical illness and MAC-ELISA testing of samples that

are not tested by RT-PCR or that are found to be negative by RT-PCR are likely to have the highest diagnostic yield.¹⁰³

The considerable cross-reactivity of flavivirus antibodies presents major challenges for the interpretation of serologic test results. For example, recent Zika virus infection may also evoke a positive MAC-ELISA result for dengue. The plaque reduction neutralization test (PRNT), the most specific test used to differentiate antibodies of closely related viruses, can be used to help verify MAC-ELISA results.¹⁰⁴ However, this test is labor-intensive and costly, involves handling of live virus, takes up to a week to perform, requires standardized reagents that often are not available, and is not widely performed. In settings where PRNT is not available or the volume of testing makes PRNT impractical, specimens that are found positive by Zika virus MAC-ELISA and negative by dengue MAC-ELISA may be interpreted as a presumptive recent Zika virus infection. However, the diagnostic accuracy of this approach has not been established.

The greatest challenge with serologic cross-reactivity arises from the “original antigenic sin” phenomenon¹⁰⁵: for patients who have previously been exposed to a heterologous flavivirus by natural infection or vaccination, the antibody response to the previous infecting flavivirus will be more vigorous than the response to the current one.^{101,106} Even the PRNT cannot reliably establish a diagnosis in such patients. This is particularly problematic in areas in which dengue is endemic, where more than 90% of the population may have had previous exposure to dengue virus¹⁰⁷ and dengue and Zika viruses may be cocirculating.

Limited data suggest that Zika virus RNA can be detected longer in urine than in serum; if verified, this would extend the period during which a definitive diagnosis of Zika virus infection can be established by RT-PCR.^{74,108-110} Another large study that compared RT-PCR results in serum and saliva samples indicated that RT-PCR had higher sensitivity in saliva than in serum, although samples from some patients were positive in serum but not saliva, and testing of saliva did not extend the duration of detectability of viral nucleic acid after the onset of illness.¹¹¹

Reliable testing regimens for the diagnosis of prenatal and antenatal Zika virus infection have not been established. Amniotic fluid has tested

positive by RT-PCR in instances of congenital Zika virus infection; however, the sensitivity of RT-PCR in this context is unknown.^{40,53,54,94,95} At the time of delivery, cord blood can be tested by RT-PCR and MAC-ELISA, but the sensitivities of these tests for detecting prenatal Zika virus infection are unknown. RT-PCR and immunohistochemical testing have been useful in establishing Zika virus infection in tissues of fetal losses and full-term infants who died shortly after birth.^{55,94}

Although microcephaly and other fetal abnormalities may be detected as early as 18 to 20 weeks of gestation,^{40,54,69,112} they are often not detected until later in pregnancy, in part because some cases do not occur earlier in pregnancy.^{69,113} Furthermore, the use of ultrasonography to detect microcephaly is dependent on clinical and technical factors,¹¹⁴ and ultrasonography is not a highly sensitive means of detecting microcephaly.¹¹⁵ Findings associated with Zika virus infection that have been noted on ultrasound have included, in addition to microcephaly, an absent corpus callosum, hydranencephaly, cerebral calcifications, ventricular dilatation, brain atrophy, abnormal gyration, hydrops fetalis, anhydramnios, and intrauterine growth retardation.^{40,69,94,116}

VIROLOGY

Despite a limited number of available full-length Zika virus sequences, the molecular data are sufficient to reveal patterns of viral evolution and movement. The virus is likely to have originated in East Africa and subsequently spread to West Africa and then to Asia, resulting in distinct lineages (Nigerian Cluster, MR766 Cluster, and the Asian genotype).^{101,117} All strains currently associated with the outbreak in the Americas are of the Asian genotype and are most closely related to strains from Yap, Cambodia, Thailand, and French Polynesia.¹¹⁸ The strains from the Americas that have been examined to date are genetically very similar to each other, with approximately 99% nucleotide homology. Furthermore, there is strong conservation among all Zika virus strains overall, with less than 12% divergence at the nucleotide level.¹¹⁹ This is important for diagnostic assays, which rely on precise sequences and epitopes, as well as for the development of therapeutics and vaccines. The current similarity data suggest that any vaccine product developed against any strain of Zika virus should be protective against all strains. The very nature of the

close relatedness among the flaviviruses is responsible for the challenges in developing diagnostic algorithms for distinguishing among these viruses.

TREATMENT, PREVENTION, AND CONTROL

As with the other mosquito-borne flaviviruses, treatment for uncomplicated Zika virus infection focuses on symptoms. No Zika virus vaccine exists; thus, prevention and control measures center on avoiding mosquito bites, reducing sexual transmission, and controlling the mosquito vector. Potentially effective methods of prevention that are focused on reducing infections among pregnant women include avoiding unnecessary travel to areas of ongoing Zika virus transmission, avoiding unprotected sexual contact with partners who are at risk for Zika virus infection,¹⁰³ and using mosquito repellent, permethrin treatment for clothing,¹²⁰ bed nets,¹²¹ window screens,^{122,123} and air conditioning.^{124,125} The most effective *A. aegypti* vector control relies on an integrated approach that involves elimination of *A. aegypti* mosquito breeding sites, application of larvicides, and application of insecticides to kill adult mosquitoes. However, each of these approaches has substantial limitations. Communities are often mobilized to reduce *A. aegypti* breeding sites, but this strategy often fails, in part because of inconsistent participation among households and the presence of cryptic breeding sites in modern urban settings.^{126,127} Dengue control programs make extensive use of peridomestic insecticide spraying during outbreaks, but little evidence supports its efficacy as a single control intervention.¹²⁸ The application of larvicides¹²⁹ and indoor residual spraying^{129,130} have been effective in some settings. Given these limitations, an integrated prevention and vector-control approach combined with timely detection of illness, communication of up-to-date and correct information, and development of a rapid response that involves the community are recommended.¹³¹

FUTURE OUTLOOK AND DIRECTIONS

The current incidence of Zika virus infection in the Americas is difficult to gauge because the symptoms are nonspecific and generally mild, laboratory diagnosis is not uniformly available,

and flavivirus antibody cross-reactivity complicates serologic assessment in areas in which dengue is endemic. Nevertheless, given the historically high incidence of dengue in the region and the recent experience with the chikungunya virus in the Americas, millions of Zika virus infections should be expected as the virus continues to spread.¹³²⁻¹³⁵ If Brazil serves as a bellwether for the rest of Latin America and the Caribbean, substantial numbers of infants with microcephaly and other adverse pregnancy outcomes could be identified in the upcoming months. The potential burden of illness from Guillain-Barré syndrome is hard to assess, given the difficulties with serologic diagnosis in areas where dengue is endemic and the paucity of published data on current incidence.

The underlying reasons for the emergence of Zika virus in the past decade are unknown. Recent global increases in the incidence and spread of dengue, chikungunya, and now Zika virus — all with *A. aegypti* as the primary vector — suggest common underlying mechanisms for their emergence, such as globalization and urbanization.^{132,136} Other possible explanations include viral mutations affecting transmission or virulence and viral introduction to previously unexposed populations leading to epidemic spread. Further research will be required to determine whether the recently observed associations with adverse birth outcomes and Guillain-Barré syndrome simply reflect an increased incidence of infection or whether they result from a change in viral virulence. In areas of Africa and Asia where Zika virus is endemic, the incidence of infection, whether outbreaks will occur, and the

reason for the previous lack of recorded cases of adverse pregnancy outcomes or Guillain-Barré syndrome are unknown. It is possible that many exposures occur in children, in whom Guillain-Barré syndrome may be less likely to develop and who would later be immune to infections during pregnancy.

The long-term outlook with regard to the current Zika virus outbreak in the Americas is uncertain. Herd immunity sufficient to slow further transmission will undoubtedly occur, although this will not obviate the need for immediate and long-term prevention and control strategies. Whether and where the virus becomes endemic and whether an enzootic transmission cycle will develop somewhere in the Americas are matters of conjecture, but they are of considerable importance for the long-term development and sustainability of countermeasures, such as a Zika virus vaccine.

What is clear is the need to rapidly and systematically address identified research gaps. These include a complete understanding of the frequency and full spectrum of clinical outcomes resulting from fetal Zika virus infection and of the environmental factors that influence emergence, as well as the development of discriminating diagnostic tools for flaviviruses, animal models for fetal developmental effects due to viral infection, new vector control products and strategies, effective therapeutics, and vaccines to protect humans against the disease.

The findings and conclusions in this review are those of the authors and do not necessarily represent the official position of the Centers for Disease Control and Prevention.

Disclosure forms provided by the authors are available with the full text of this article at NEJM.org.

REFERENCES

- Dick GW, Kitchen SF, Haddock AJ. Zika virus. I. Isolations and serological specificity. *Trans R Soc Trop Med Hyg* 1952;46:509-20.
- Fauci AS, Morens DM. Zika virus in the Americas — yet another arbovirus threat. *N Engl J Med* 2016;374:601-4.
- Gulland A. Zika virus is a global public health emergency, declares WHO. *BMJ* 2016;352:i657.
- Dick GW. Zika virus. II. Pathogenicity and physical properties. *Trans R Soc Trop Med Hyg* 1952;46:521-34.
- Dick GW. Epidemiological notes on some viruses isolated in Uganda; Yellow fever, Rift Valley fever, Bwamba fever, West Nile, Mengo, Semliki forest, Bunyamwera, Ntaya, Uganda S and Zika viruses. *Trans R Soc Trop Med Hyg* 1953;47:13-48.
- Smithburn KC, Taylor RM, Rizk F, Kader A. Immunity to certain arthropod-borne viruses among indigenous residents of Egypt. *Am J Trop Med Hyg* 1954;3:9-18.
- Smithburn KC. Neutralizing antibodies against certain recently isolated viruses in the sera of human beings residing in East Africa. *J Immunol* 1952;69:223-34.
- MacNamara FN. Zika virus: a report on three cases of human infection during an epidemic of jaundice in Nigeria. *Trans R Soc Trop Med Hyg* 1954;48:139-45.
- Smithburn KC, Kerr JA, Gatne PB. Neutralizing antibodies against certain viruses in the sera of residents of India. *J Immunol* 1954;72:248-57.
- Pond WL. Arthropod-borne virus antibodies in sera from residents of South-East Asia. *Trans R Soc Trop Med Hyg* 1963;57:364-71.
- Hammon WM, Schrack WD Jr, Sather GE. Serological survey for an arthropod-borne virus infections in the Philippines. *Am J Trop Med Hyg* 1958;7:323-8.
- Smithburn KC. Neutralizing antibodies against arthropod-borne viruses in the sera of long-time residents of Malaya and Borneo. *Am J Hyg* 1954;59:157-63.
- Fagbami AH. Zika virus infections in Nigeria: virological and seroepidemiological investigations in Oyo State. *J Hyg (Lond)* 1979;83:213-9.

14. Moore DL, Causey OR, Carey DE, et al. Arthropod-borne viral infections of man in Nigeria, 1964-1970. *Ann Trop Med Parasitol* 1975;69:49-64.
15. Olson JG, Ksiazek TG, Suhandiman, Triwibowo. Zika virus, a cause of fever in Central Java, Indonesia. *Trans R Soc Trop Med Hyg* 1981;75:389-93.
16. Simpson DI. Zika virus infection in man. *Trans R Soc Trop Med Hyg* 1964;58:335-8.
17. Duffy MR, Chen T-H, Hancock WT, et al. Zika virus outbreak on Yap Island, Federated States of Micronesia. *N Engl J Med* 2009;360:2536-43.
18. Cao-Lormeau VM, Roche C, Teissier A, et al. Zika virus, French Polynesia, South Pacific, 2013. *Emerg Infect Dis* 2014;20:1085-6.
19. Rapid risk assessment: Zika virus infection outbreak, French Polynesia. Stockholm: European Centre for Disease Prevention and Control, February 14, 2014 (<http://ecdc.europa.eu/en/publications/Publications/Zika-virus-French-Polynesia-rapid-risk-assessment.pdf>).
20. Mallet H-P, Vial A-L, Musso D. Bilan de l'épidémie à virus Zika en Polynésie Française, 2013-2014. May 2015 (http://www.hygiene-publique.gov.pf/IMG/pdf/no13_-_mai_2015_-_zika.pdf).
21. Oehler E, Watrin L, Larre P, et al. Zika virus infection complicated by Guillain-Barré syndrome — case report, French Polynesia, December 2013. *Euro Surveill* 2014;19(9).
22. Dupont-Rouzeyrol M, O'Connor O, Calvez E, et al. Co-infection with Zika and dengue viruses in 2 patients, New Caledonia, 2014. *Emerg Infect Dis* 2015;21:381-2.
23. Tognarelli J, Ulloa S, Villagra E, et al. A report on the outbreak of Zika virus on Easter Island, South Pacific, 2014. *Arch Virol* 2016;161:665-8.
24. Roth A, Mercier A, Lepers C, et al. Concurrent outbreaks of dengue, chikungunya and Zika virus infections — an unprecedented epidemic wave of mosquito-borne viruses in the Pacific 2012-2014. *Euro Surveill* 2014;19(41).
25. Buathong R, Hermann L, Thaisomboonsuk B, et al. Detection of Zika virus infection in Thailand, 2012-2014. *Am J Trop Med Hyg* 2015;93:380-3.
26. Tappe D, Rissland J, Gabriel M, et al. First case of laboratory-confirmed Zika virus infection imported into Europe, November 2013. *Euro Surveill* 2014;19(4).
27. Tappe D, Nachtigall S, Kapaun A, Schnitzler P, Günther S, Schmidt-Chanais J. Acute Zika virus infection after travel to Malaysian Borneo, September 2014. *Emerg Infect Dis* 2015;21:911-3.
28. Heang V, Yasuda CY, Sovann L, et al. Zika virus infection, Cambodia, 2010. *Emerg Infect Dis* 2012;18:349-51.
29. Alera MT, Hermann L, Tac-An IA, et al. Zika virus infection, Philippines, 2012. *Emerg Infect Dis* 2015;21:722-4.
30. Kwong JC, Druce JD, Leder K. Zika virus infection acquired during brief travel to Indonesia. *Am J Trop Med Hyg* 2013;89:516-7.
31. Perkasa A, Yudhaputri F, Haryanto S, et al. Isolation of Zika virus from febrile patient, Indonesia. *Emerg Infect Dis* 2016 (in press).
32. Campos GS, Bandeira AC, Sardi SI. Zika virus outbreak, Bahia, Brazil. *Emerg Infect Dis* 2015;21:1885-6.
33. Zanluca C, Melo VC, Mosimann AL, Santos GI, Santos CN, Luz K. First report of autochthonous transmission of Zika virus in Brazil. *Mem Inst Oswaldo Cruz* 2015;110:569-72.
34. Cardoso CW, Paploski IA, Kikuti M, et al. Outbreak of exanthematous illness associated with Zika, chikungunya, and dengue viruses, Salvador, Brazil. *Emerg Infect Dis* 2015;21:2274-6.
35. Zika virus outbreaks in the Americas. *Wkly Epidemiol Rec* 2015;90:609-10.
36. Zika virus spreads to new areas — region of the Americas, May 2015–January 2016. *MMWR Morb Mortal Wkly Rep* 2016;65:55-8.
37. Zika virus microcephaly and Guillain-Barré syndrome. Geneva: World Health Organization, March 17, 2016 (http://apps.who.int/iris/bitstream/10665/204633/1/zikasitrep_17Mar2016_eng.pdf).
38. Possible association between Zika virus infection and microcephaly — Brazil, 2015. *MMWR Morb Mortal Wkly Rep* 2016;65:59-62.
39. Victora CG, Schuler-Faccini L, Matijasevich A, Ribeiro E, Pessoa A, Barros FC. Microcephaly in Brazil: how to interpret reported numbers? *Lancet* 2016;387:621-4.
40. Jouannic JM, Friszer S, Leparc-Goffart I, Garel C, Eyrolle-Guignot D. Zika virus infection in French Polynesia. *Lancet* 2016 March 1 (Epub ahead of print).
41. Cauchemez S, Besnard M, Bompard P, et al. Association between Zika virus and microcephaly in French Polynesia, 2013-15: a retrospective study. *Lancet* 2016 March 15 (Epub ahead of print).
42. Diallo D, Sall AA, Diagne CT, et al. Zika virus emergence in mosquitoes in southeastern Senegal, 2011. *PLoS One* 2014;9(10):e109442.
43. Marchette NJ, Garcia R, Rudnick A. Isolation of Zika virus from *Aedes aegypti* mosquitoes in Malaysia. *Am J Trop Med Hyg* 1969;18:411-5.
44. Grard G, Caron M, Mombo IM, et al. Zika virus in Gabon (Central Africa) — 2007: a new threat from *Aedes albopictus*? *PLoS Negl Trop Dis* 2014;8(2):e2681.
45. Ledermann JP, Guillaumot L, Yug L, et al. *Aedes hensilli* as a potential vector of Chikungunya and Zika viruses. *PLoS Negl Trop Dis* 2014;8(10):e3188.
46. Musso D, Nilles EJ, Cao-Lormeau VM. Rapid spread of emerging Zika virus in the Pacific area. *Clin Microbiol Infect* 2014;20:0595-6.
47. Chouin-Carneiro T, Vega-Rua A, Vazeille M, et al. Differential susceptibilities of *Aedes aegypti* and *Aedes albopictus* from the Americas to Zika virus. *PLoS Negl Trop Dis* 2016;10(3):e0004543.
48. Gubler DJ. The global emergence/resurgence of arboviral diseases as public health problems. *Arch Med Res* 2002;33:330-42.
49. Monaghan AJ, Morin CW, Steinhoff DF, et al. On the seasonal occurrence and abundance of the Zika virus vector mosquito *Aedes aegypti* in the contiguous United States. *PLoS Curr* 2016 March 16. Edition 1 (<http://currents.plos.org/outbreaks/article/on-the-seasonal-occurrence-and-abundance-of-the-zika-virus-vector-mosquito-aedes-aegypti-in-the-contiguous-united-states/>).
50. Effler PV, Pang L, Kitsutani P, et al. Dengue fever, Hawaii, 2001-2002. *Emerg Infect Dis* 2005;11:742-9.
51. Notes from the field: outbreak of locally acquired cases of dengue fever — Hawaii, 2015. *MMWR Morb Mortal Wkly Rep* 2016;65:34-5.
52. Calvet G, Aguiar RS, Melo AS, et al. Detection and sequencing of Zika virus from amniotic fluid of fetuses with microcephaly in Brazil: a case study. *Lancet Infect Dis* 2016 February 17 (Epub ahead of print).
53. Oliveira Melo AS, Malinger G, Ximenes R, Szejnfeld PO, Alves Sampaio S, Bispo de Filippis AM. Zika virus intrauterine infection causes fetal brain abnormality and microcephaly: tip of the iceberg? *Ultrasound Obstet Gynecol* 2016;47:6-7.
54. Zika virus infection among U.S. pregnant travelers — August 2015–February 2016. *MMWR Morb Mortal Wkly Rep* 2016;65:211-4.
55. Notes from the field: evidence of Zika virus infection in brain and placental tissues from two congenitally infected newborns and two fetal losses — Brazil, 2015. *MMWR Morb Mortal Wkly Rep* 2016;65:159-60.
56. Besnard M, Lastere S, Teissier A, Cao-Lormeau V, Musso D. Evidence of perinatal transmission of Zika virus, French Polynesia, December 2013 and February 2014. *Euro Surveill* 2014;19(13).
57. Foy BD, Kobylinski KC, Chilson Foy JL, et al. Probable non-vector-borne transmission of Zika virus, Colorado, USA. *Emerg Infect Dis* 2011;17:880-2.
58. Transmission of Zika virus through sexual contact with travelers to areas of ongoing transmission — continental United States, 2016. *MMWR Morb Mortal Wkly Rep* 2016;65:215-6.
59. Venturi G, Zammarchi L, Fortuna C, et al. An autochthonous case of Zika due to possible sexual transmission, Florence, Italy, 2014. *Euro Surveill* 2016;21(8).
60. Musso D, Roche C, Robin E, Nhan T, Teissier A, Cao-Lormeau VM. Potential sexual transmission of Zika virus. *Emerg Infect Dis* 2015;21:359-61.

61. Atkinson B, Hearn P, Afrough B, et al. Detection of Zika virus in semen. *Emerg Infect Dis* 2016 May (Epub ahead of print).
62. Mansuy JM, Dutertre M, Mengelle C, et al. Zika virus: high infectious viral load in semen, a new sexually transmitted pathogen? *Lancet Infect Dis* 2016 March 3 (Epub ahead of print).
63. Marano G, Pupella S, Vaglio S, Liunbruno GM, Grazzini G. Zika virus and the never-ending story of emerging pathogens and transfusion medicine. *Blood Transfus* 2016;14:95-100.
64. Musso D, Nhan T, Robin E, et al. Potential for Zika virus transmission through blood transfusion demonstrated during an outbreak in French Polynesia, November 2013 to February 2014. *Euro Surveill* 2014;19(14).
65. Leung GH, Baird RW, Druce J, Anstey NM. Zika virus infection in Australia following a monkey bite in Indonesia. *Southeast Asian J Trop Med Public Health* 2015; 46:460-4.
66. Filipe AR, Martins CM, Rocha H. Laboratory infection with Zika virus after vaccination against yellow fever. *Arch Gesamte Virusforsch* 1973;43:315-9.
67. Bearcroft WG. Zika virus infection experimentally induced in a human volunteer. *Trans R Soc Trop Med Hyg* 1956;50: 442-8.
68. Dupont-Rouzeyrol M, Biron A, O'Connor O, Huguon E, Descloux E. Infectious Zika viral particles in breastmilk. *Lancet* 2016 March 1 (Epub ahead of print).
69. Brasil P, Pereira JP Jr, Raja Gabaglia C, et al. Zika virus infection in pregnant women in Rio de Janeiro — preliminary report. *N Engl J Med*. DOI: 10.1056/NEJMoa1602412.
70. Zammarchi L, Stella G, Mantella A, et al. Zika virus infections imported to Italy: clinical, immunological and virological findings, and public health implications. *J Clin Virol* 2015;63:32-5.
71. Karimi O, Goorhuis A, Schinkel J, et al. Thrombocytopenia and subcutaneous bleedings in a patient with Zika virus infection. *Lancet* 2016;387:939-40.
72. Local transmission of Zika virus — Puerto Rico, November 23, 2015–January 28, 2016. *MMWR Morb Mortal Wkly Rep* 2016;65:154-8.
73. Broutet N, Krauer F, Riesen M, et al. Zika virus as a cause of neurologic disorders. *N Engl J Med* 2016;374:1506-9.
74. Rozé B, Najjioullah F, Fergé JL, et al. Zika virus detection in urine from patients with Guillain-Barré syndrome on Martinique, January 2016. *Euro Surveill* 2016;21(9).
75. Cao-Lormeau VM, Blake A, Mons S, et al. Guillain-Barré Syndrome outbreak associated with Zika virus infection in French Polynesia: a case-control study. *Lancet* 2016 February 29 (Epub ahead of print).
76. Carreau G, Maquart M, Bedet A, et al. Zika virus associated with meningoencephalitis. *N Engl J Med* 2016;374:1595-6.
77. Mécharles S, Herrmann C, Poullain P, et al. Acute myelitis due to Zika virus infection. *Lancet* 2016 March 3 (Epub ahead of print).
78. Webster WS. Teratogen update: congenital rubella. *Teratology* 1998;58:13-23.
79. Ahlfors K, Ivarsson SA, Harris S. Report on a long-term study of maternal and congenital cytomegalovirus infection in Sweden: review of prospective studies available in the literature. *Scand J Infect Dis* 1999;31:443-57.
80. Miller E, Craddock-Watson JE, Pollock TM. Consequences of confirmed maternal rubella at successive stages of pregnancy. *Lancet* 1982;2:781-4.
81. Peckham CS. Clinical and laboratory study of children exposed in utero to maternal rubella. *Arch Dis Child* 1972;47: 571-7.
82. Rorke LB. Nervous system lesions in the congenital rubella syndrome. *Arch Otolaryngol* 1973;98:249-51.
83. Weller TH, Hanshaw JB, Scott DE. Virologic and clinical observations on cytomegalic inclusion disease. *N Engl J Med* 1962;266:1233-44.
84. Pass RF, Fowler KB, Boppana SB, Britt WJ, Stagno S. Congenital cytomegalovirus infection following first trimester maternal infection: symptoms at birth and outcome. *J Clin Virol* 2006;35:216-20.
85. Foulon I, Naessens A, Faron G, Foulon W, Jansen AC, Gordts F. Hearing thresholds in children with a congenital CMV infection: a prospective study. *Int J Pediatr Otorhinolaryngol* 2012;76:712-7.
86. Alcantara D, O'Driscoll M. Congenital microcephaly. *Am J Med Genet C Semin Med Genet* 2014;166C:124-39.
87. Woods CG, Parker A. Investigating microcephaly. *Arch Dis Child* 2013;98: 707-13.
88. Update: interim guidelines for health care providers caring for infants and children with possible Zika virus infection — United States, February 2016. *MMWR Morb Mortal Wkly Rep* 2016;65:182-7.
89. National Birth Defects Prevention Network. Major birth defects data from population-based birth defects surveillance programs in the United States, 2006-2010. August 2013 (http://www.nbdpn.org/docs/DataDirectory2013_NBDPN_AR.pdf).
90. Moore CA, Weaver DD, Bull MJ. Fetal brain disruption sequence. *J Pediatr* 1990; 116:383-6.
91. Rasmussen SA, Frias JL. Fetal brain disruption sequence: a brief case report. *Dysmorph Clin Genet* 1990;4:53-6.
92. Corona-Rivera JR, Corona-Rivera E, Romero-Velarde E, Hernández-Rocha J, Bobadilla-Morales L, Corona-Rivera A. Report and review of the fetal brain disruption sequence. *Eur J Pediatr* 2001;160: 664-7.
93. Gabis L, Gelman-Kohan Z, Mogilner M. Microcephaly due to fetal brain disruption sequence: case report. *J Perinat Med* 1997;25:213-5.
94. Mlakar J, Korva M, Tul N, et al. Zika virus associated with microcephaly. *N Engl J Med* 2016;374:951-8.
95. Driggers RW, Ho C-Y, Korhonen EM, et al. Zika virus infection with prolonged maternal viremia and fetal brain abnormalities. *N Engl J Med*. DOI: 10.1056/NEJMoa1601824.
96. Increase in reported prevalence of microcephaly in infants born to women living in areas with confirmed Zika virus transmission during the first trimester of pregnancy — Brazil, 2015. *MMWR Morb Mortal Wkly Rep* 2016;65:242-7.
97. Reefhuis J, Gilboa SM, Johansson MA, et al. Projecting month of birth for at-risk infants after Zika virus disease outbreaks. *Emerg Infect Dis* 2016. (in press).
98. Ventura CV, Maia M, Bravo-Filho V, Góis AL, Belfort R Jr. Zika virus in Brazil and macular atrophy in a child with microcephaly. *Lancet* 2016;387:228.
99. Ventura CV, Maia M, Ventura BV, et al. Ophthalmological findings in infants with microcephaly and presumable intra-uterus Zika virus infection. *Arq Bras Oftalmol* 2016;79:1-3.
100. de Paula Freitas B, de Oliveira Dias JR, Prazeres J, et al. Ocular findings in infants with microcephaly associated with presumed Zika virus congenital infection in Salvador, Brazil. *JAMA Ophthalmol* 2016 February 9 (Epub ahead of print).
101. Lanciotti RS, Kosoy OL, Laven JJ, et al. Genetic and serologic properties of Zika virus associated with an epidemic, Yap State, Micronesia, 2007. *Emerg Infect Dis* 2008;14:1232-9.
102. Busch MP, Kleinman SH, Tobler LH, et al. Virus and antibody dynamics in acute West Nile virus infection. *J Infect Dis* 2008;198:984-93.
103. Update: interim guidelines for health care providers caring for pregnant women and women of reproductive age with possible Zika virus exposure — United States, 2016. *MMWR Morb Mortal Wkly Rep* 2016;65:122-7.
104. Roehrig JT, Hombach J, Barrett AD. Guidelines for plaque-reduction neutralization testing of human antibodies to dengue viruses. *Viral Immunol* 2008;21: 123-32.
105. Morens DM, Burke DS, Halstead SB. The wages of original antigenic sin. *Emerg Infect Dis* 2010;16:1023-4.
106. Johnson BW, Kosoy O, Martin DA, et al. West Nile virus infection and serologic response among persons previously vaccinated against yellow fever and Japanese encephalitis viruses. *Vector Borne Zoonotic Dis* 2005;5:137-45.
107. Mohammed H, Tomashak KM, Stramer SL, Hunsperger E. Prevalence of anti-dengue immunoglobulin G antibodies among American Red Cross blood donors

- in Puerto Rico, 2006. *Transfusion* 2012; 52:1652-6.
108. Gourinat AC, O'Connor O, Calvez E, Goarant C, Dupont-Rouzeyrol M. Detection of Zika virus in urine. *Emerg Infect Dis* 2015;21:84-6.
109. Kutsuna S, Kato Y, Takasaki T, et al. Two cases of Zika fever imported from French Polynesia to Japan, December 2013 to January 2014. *Euro Surveill* 2014;19(4).
110. Korhonen EM, Huhtamo E, Smura T, Kallio-Kokko H, Raassina M, Vapalahti O. Zika virus infection in a traveller returning from the Maldives, June 2015. *Euro Surveill* 2016;21(2).
111. Musso D, Roche C, Nhan TX, Robin E, Teissier A, Cao-Lormeau VM. Detection of Zika virus in saliva. *J Clin Virol* 2015; 68:53-5.
112. den Hollander NS, Wessels MW, Los FJ, Ursem NT, Niermeijer MF, Wladimiroff JW. Congenital microcephaly detected by prenatal ultrasound: genetic aspects and clinical significance. *Ultrasound Obstet Gynecol* 2000;15:282-7.
113. Bromley B, Benacerraf BR. Difficulties in the prenatal diagnosis of microcephaly. *J Ultrasound Med* 1995;14:303-6.
114. Reddy UM, Abuhamad AZ, Levine D, Saade GR. Fetal imaging: executive summary of a Joint Eunice Kennedy Shriver National Institute of Child Health and Human Development, Society for Maternal-Fetal Medicine, American Institute of Ultrasound in Medicine, American College of Obstetricians and Gynecologists, American College of Radiology, Society for Pediatric Radiology, and Society of Radiologists in Ultrasound Fetal Imaging Workshop. *Am J Obstet Gynecol* 2014; 210:387-97.
115. Leibovitz Z, Daniel-Spiegel E, Malinger G, et al. Microcephaly at birth — the accuracy of three references for fetal head circumference: how can we improve prediction? *Ultrasound Obstet Gynecol* 2015.
116. Sarno M, Sacramento GA, Khouri R, et al. Zika virus infection and stillbirths: a case of hydrops fetalis, hydranencephaly and fetal demise. *PLoS Negl Trop Dis* 2016;10(2):e0004517.
117. Faye O, Freire CC, Iamarino A, et al. Molecular evolution of Zika virus during its emergence in the 20(th) century. *PLoS Negl Trop Dis* 2014;8(1):e2636.
118. Lanciotti RS, Lambert AJ, Holodniv M, Saavedra S, del Carmen Castillo Signor L. Phylogeny of Zika virus in Western Hemisphere. *Emerg Infect Dis* 2016 (in press).
119. Haddow AD, Schuh AJ, Yasuda CY, et al. Genetic characterization of Zika virus strains: geographic expansion of the Asian lineage. *PLoS Negl Trop Dis* 2012;6(2): e1477.
120. Banks SD, Murray N, Wilder-Smith A, Logan JG. Insecticide-treated clothes for the control of vector-borne diseases: a review on effectiveness and safety. *Med Vet Entomol* 2014;28:Suppl 1:14-25.
121. Lenhart A, Orelus N, Maskill R, Alexander N, Streit T, McCall PJ. Insecticide-treated bednets to control dengue vectors: preliminary evidence from a controlled trial in Haiti. *Trop Med Int Health* 2008; 13:56-67.
122. Manrique-Saide P, Che-Mendoza A, Barrera-Perez M, et al. Use of insecticide-treated house screens to reduce infestations of dengue virus vectors, Mexico. *Emerg Infect Dis* 2015;21:308-11.
123. Che-Mendoza A, Guillermo-May G, Herrera-Bojórquez J, et al. Long-lasting insecticide-treated house screens and targeted treatment of productive breeding-sites for dengue vector control in Acapulco, Mexico. *Trans R Soc Trop Med Hyg* 2015;109:106-15.
124. Brunkard JM, Robles López JL, Ramirez J, et al. Dengue fever seroprevalence and risk factors, Texas-Mexico border, 2004. *Emerg Infect Dis* 2007;13:1477-83.
125. Reiter P, Lathrop S, Bunning M, et al. Texas lifestyle limits transmission of dengue virus. *Emerg Infect Dis* 2003;9:86-9.
126. Heintze C, Velasco Garrido M, Kroeger A. What do community-based dengue control programmes achieve? A systematic review of published evaluations. *Trans R Soc Trop Med Hyg* 2007; 101:317-25.
127. Barrera R, Amador M, Diaz A, Smith J, Munoz-Jordan JL, Rosario Y. Unusual productivity of *Aedes aegypti* in septic tanks and its implications for dengue control. *Med Vet Entomol* 2008;22:62-9.
128. Esu E, Lenhart A, Smith L, Horstick O. Effectiveness of peridomestic space spraying with insecticide on dengue transmission; systematic review. *Trop Med Int Health* 2010;15:619-31.
129. Vazquez-Prokopec GM, Kitron U, Montgomery B, Horne P, Ritchie SA. Quantifying the spatial dimension of dengue virus epidemic spread within a tropical urban environment. *PLoS Negl Trop Dis* 2010;4(12):e920.
130. Paredes-Esquivel C, Lenhart A, Del Río R, et al. The impact of indoor residual spraying of deltamethrin on dengue vector populations in the Peruvian Amazon. *Acta Trop* 2016;154:139-44.
131. Adalja AA, Sell TK, Bouri N, Franco C. Lessons learned during dengue outbreaks in the United States, 2001-2011. *Emerg Infect Dis* 2012;18:608-14.
132. Musso D, Cao-Lormeau VM, Gubler DJ. Zika virus: following the path of dengue and chikungunya? *Lancet* 2015;386: 243-4.
133. Bhatt S, Gething PW, Brady OJ, et al. The global distribution and burden of dengue. *Nature* 2013;496:504-7.
134. Weaver SC, Lecuit M. Chikungunya virus and the global spread of a mosquito-borne disease. *N Engl J Med* 2015;372: 1231-9.
135. Leparac-Goffart I, Nougairede A, Cassadou S, Prat C, de Lamballerie X. Chikungunya in the Americas. *Lancet* 2014; 383:514.
136. Wilder-Smith A, Gubler DJ. Geographic expansion of dengue: the impact of international travel. *Med Clin North Am* 2008;92:1377-90.

Copyright © 2016 Massachusetts Medical Society.

IMAGES IN CLINICAL MEDICINE

The *Journal* welcomes consideration of new submissions for Images in Clinical Medicine. Instructions for authors and procedures for submissions can be found on the *Journal's* website at NEJM.org. At the discretion of the editor, images that are accepted for publication may appear in the print version of the *Journal*, the electronic version, or both.